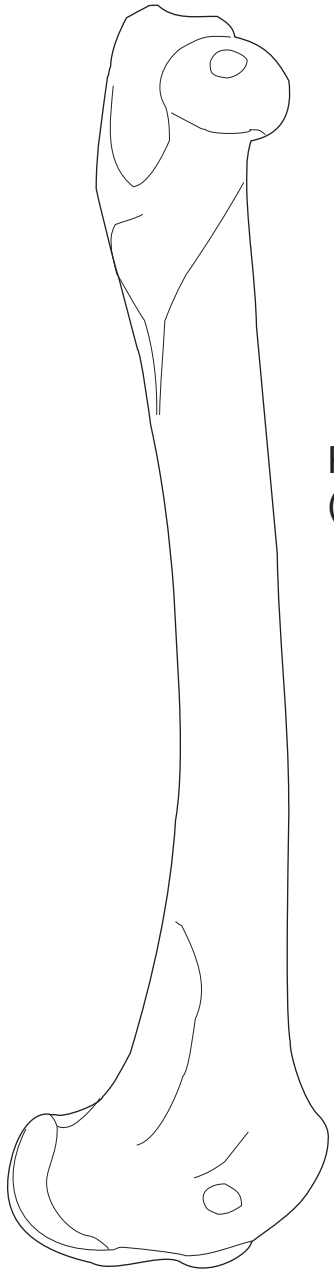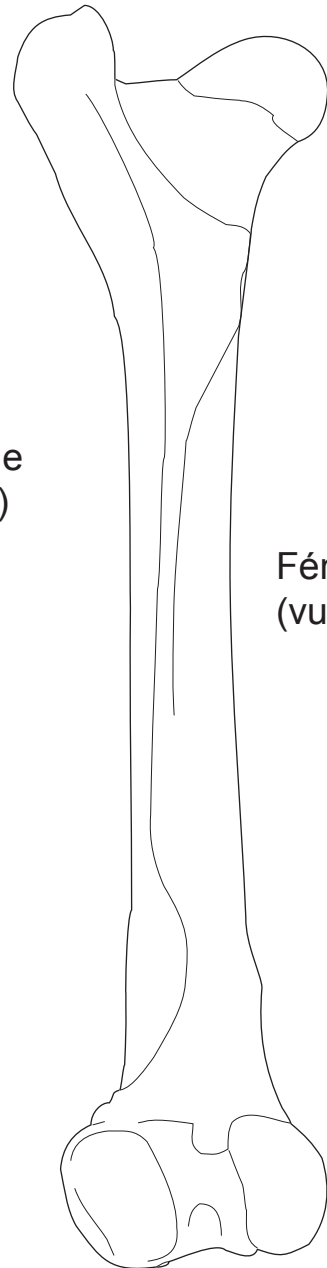
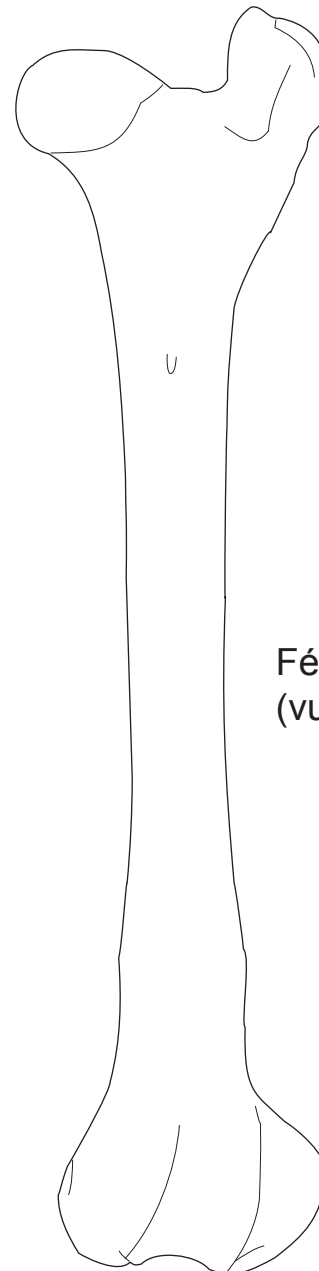


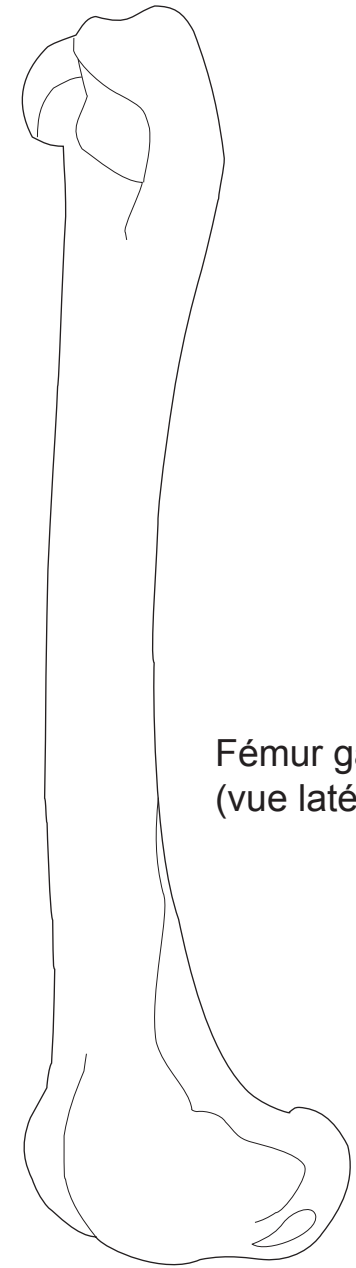
Fémur gauche
(vue médiale)



Fémur gauche
(vue caudale)



Fémur gauche
(vue crâniale)



Fémur gauche
(vue latérale)